

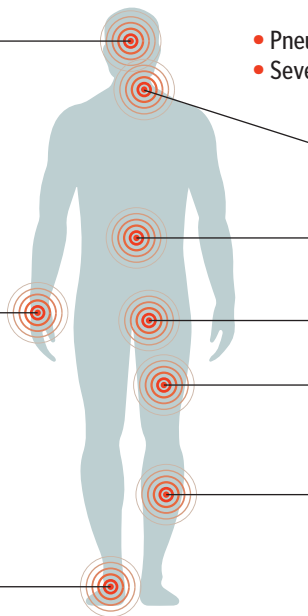
Abuse victim's injuries

- Visual disability
- Wounds on scalp and face
- Deformities to both ears
- 10 missing teeth

- Pneumonia
- Severe malnutrition

Left wrist deformity

Left second toe deformity



Burns on the neck, trunk, buttocks, thighs and legs